

The Auriculotemporal Nerve in Etiology of Migraine Headaches: Compression Points and Anatomical Variations

Harvey Chim, M.D.
Haruko C. Okada, M.D.
Matthew S. Brown, M.D.
Brendan Alleyne, B.S.
Mengyuan T. Liu, B.S.
Samantha Zwiebel, B.A.
Bahman Guyuron, M.D.

Cleveland, Ohio

Background: The auriculotemporal nerve has been identified as one of the peripheral trigger sites for migraine headaches. However, its distal course is poorly mapped following emergence from the parotid gland. In addition, a reliable anatomical landmark for locating the potential compression points along the course of the nerve during surgery has not been sufficiently described.

Methods: Twenty hemifaces on 10 fresh cadavers were dissected to trace the course of the auriculotemporal nerve from the inferior border of the zygomatic arch to its termination in the temporal scalp. The compression points were mapped and the distances were measured from the most anterosuperior point of the external auditory meatus, which was used as a fixed anatomical landmark.

Results: Three potential compression points along the course of the auriculotemporal nerve were identified. Compression points 1 and 2 corresponded to preauricular fascial bands. Compression point 1 was centered 13.1 ± 5.9 mm anterior and 5.0 ± 7.0 mm superior to the most anterosuperior point of the external auditory meatus, whereas compression point 2 was centered at 11.9 ± 6.0 mm anterior and 17.2 ± 10.4 mm superior to the most anterosuperior point of the external auditory meatus. A significant relationship was found between the auriculotemporal nerve and superficial temporal artery (compression point 3) in 80 percent of hemifaces, with three patterns of interaction: a single site of artery crossing over the nerve (62.5 percent), a helical intertwining relationship (18.8 percent), and nerve crossing over the artery (18.8 percent).

Conclusion: Findings from this cadaver study provide information relevant to the operative localization of potential compression points along the auriculotemporal nerve. (*Plast. Reconstr. Surg.* 130: 336, 2012.)

Increasing evidence in the published literature lends credence to the peripheral trigger point theory of migraine headaches.^{1,2} Decompression of the four main peripheral trigger sites (i.e., frontal, temporal, septal/turbinates, and occipital) in treatment of migraine headaches has a reported success rate of between 75 and 92 percent of patients.^{3–6} However, there remains a subset of patients who do not respond to decompression of the four main trigger points and present with persistent pain, which frequently necessitates additional surgery.

Three minor peripheral trigger points have been described that may account for persistence

of pain in some patients, and include the lesser occipital,⁷ the third occipital, and the auriculotemporal⁸ nerves. Although patients requiring surgery to decompress these minor trigger points are very rare, comprehensive surgical treatment for migraine headaches requires attention to all possible migraine trigger points. Up to 14 “myofascial trigger points” for migraine have been described in the neurology literature.^{1,9} These may in fact represent known and as yet undiscovered migraine trigger points caused by nerve compression.

In the senior author’s (B.G.) practice, 15 patients have benefited from surgery to decompress the auriculotemporal nerve. These patients usually

From the Department of Plastic Surgery, Case Western Reserve University.

Received for publication December 20, 2011; accepted February 9, 2012.

Copyright ©2012 by the American Society of Plastic Surgeons

DOI: 10.1097/PRS.0b013e3182589dd5

Disclosure: The authors declare that they had no financial interests or commercial associations relevant to this study.

present with pain in the temporal region, with pain localized to the course of the auriculotemporal nerve. The senior author's technique consists of a short incision directly over the area of maximal pain, with ligation and removal of the superficial artery if the artery was crossing over the nerve, or transection of the auriculotemporal nerve and subsequent burying in adjacent temporalis muscle if there was no artery identified in the area of the pain. The auriculotemporal nerve is extremely small and difficult to identify from surrounding structures.

This study is intended to complement a previous study that described the course of the auriculotemporal nerve in the high temple.⁴ The aim of this anatomical study was to dissect the auriculotemporal nerve along its entire course after its emergence from the parotid gland and to determine the relationship of potential compression points to a fixed anatomical landmark.

MATERIALS AND METHODS

Twenty sides on 10 cadavers were selected for this study. The most anterosuperior point of the external auditory meatus, at the junction of the tragus and root of the helix, was used as a fixed anatomical landmark. A silk suture was used to connect the corresponding point on each hemiface, and a horizontal line was drawn connecting the landmark on each side anteriorly on the face and posteriorly along the occipital scalp. A corresponding vertical line was drawn at right angles extending cephalically and caudally from the fixed landmark on each hemiface.

A preauricular face-lift incision was then made, with an extension into the temporal scalp to allow exploration of the entire course of the auriculotemporal nerve distal to its emergence from the parotid gland (Fig. 1). A skin flap was raised superficial to the superficial musculoaponeurotic system in the face and the temporoparietal fascia in the temporal scalp. The auriculotemporal nerve was identified in the preauricular area and in the temple, and the entire course of the nerve from the inferior border of the zygomatic arch to the terminal branches in the temple was dissected to identify potential compression points. The relationship between the nerve and the superficial temporal artery was also carefully observed. Horizontal and vertical distances of compression points from the most anterosuperior point of the external auditory meatus were measured.

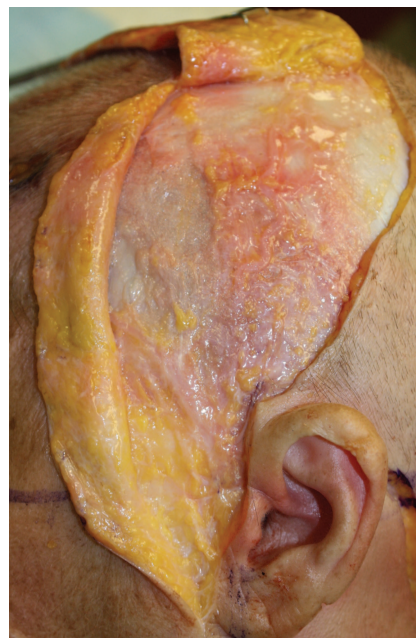

Fig. 1. A preauricular face-lift incision was made extending into the temporal scalp and raised superficial to the superficial musculoaponeurotic system and the temporoparietal fascia in the scalp to allow exploration of the auriculotemporal nerve along its entire course from the inferior border of the zygomatic arch.

RESULTS

Compression Points 1 and 2: Preauricular Fascia Bands

Two constant fascia bands in the superior preauricular bands were found (Fig. 2). The inferior band (compression point 1) was present in all specimens. The superior band (compression point 2) was present in 17 of 20 hemifaces (85 percent). The inferior fascia band was located at a mean distance of 13.1 ± 5.9 mm anterior to the most anterosuperior most point of the external auditory meatus and 5.0 ± 7.0 mm superior to the most anterosuperior point of the external auditory meatus. The superior fascia band was located at a mean distance of 11.9 ± 6.0 mm anterior to the most anterosuperior point of the external auditory meatus and 17.2 ± 10.4 mm superior to the most anterosuperior point of the external auditory meatus. The fascia bands varied in morphology, with some specimens demonstrating thicker bands (Fig. 2, *left*) and others having thinner bands (Fig. 2, *right*).

Compression Point 3: Interaction with the Superficial Temporal Artery

A crossover between the auriculotemporal and the superficial temporal artery in the temporal scalp

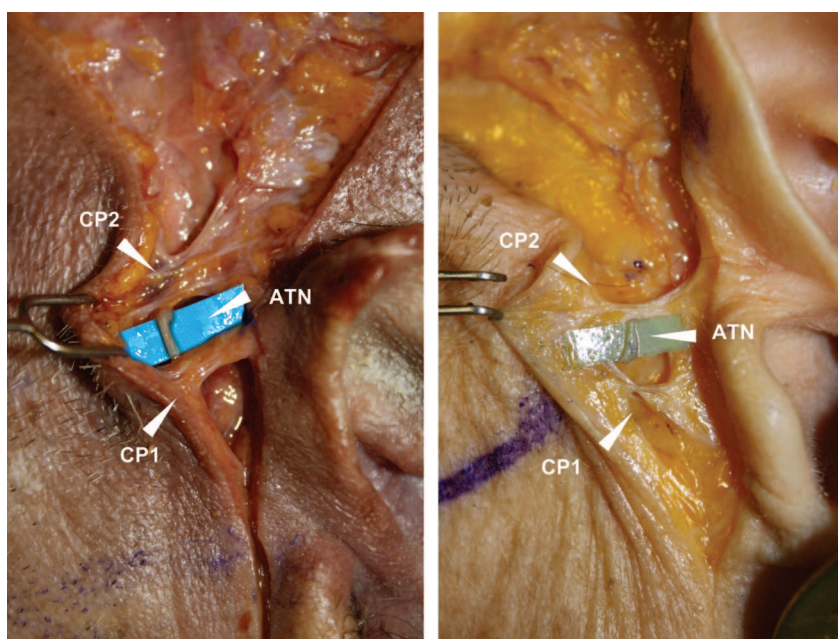


Fig. 2. Constant fascia bands were found in the superior preauricular region overlying the auriculotemporal nerve (ATN). The inferior band was designated compression point 1 (CP1) and the superior band was designated compression point 2 (CP2). The fascia bands varied in morphology and were thicker in some specimens (*left*) and thinner in others (*right*).

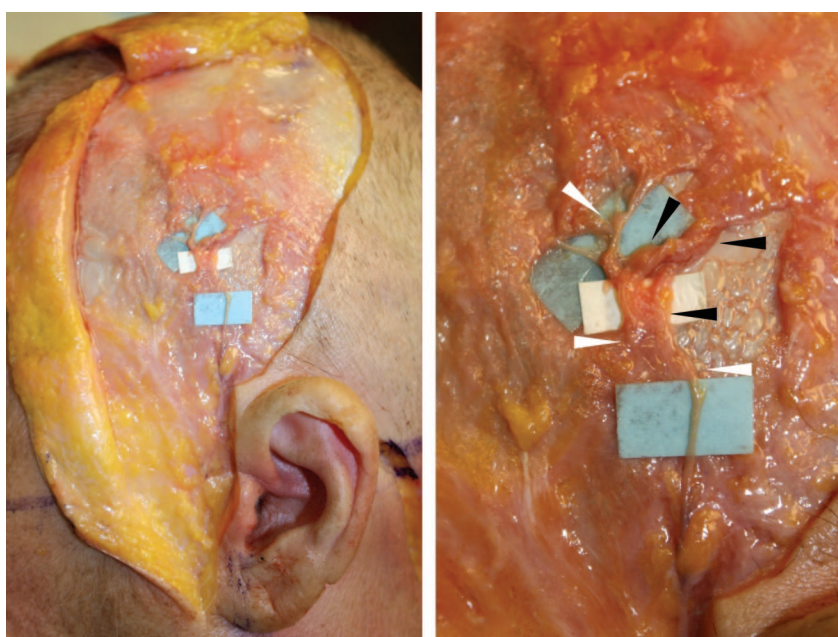


Fig. 3. Helical intertwining relationship of the auriculotemporal nerve and superficial temporal artery. An overview (*left*) and close-up (*right*) of the same cadaver dissection are shown. In this specimen (*right*), the auriculotemporal nerve (white arrowheads) passes deep to the superficial temporal artery (black arrowheads).

was found in 16 of 20 hemifaces (80 percent). This crossover fell into three groups. The most common relationship was a single type, with the artery crossing over the nerve and causing a focal point of compression. This relationship was seen in 10 of 16 hemifaces (62.5 percent). This site was found at a mean distance of 19.2 ± 10.0 mm anterior and 39.5 ± 16.6 mm superior to the most anterosuperior point of the external auditory meatus.

In three specimens (18.8 percent), there was a helical intertwining of the auriculotemporal nerve and the superficial temporal artery (Fig. 3). The caudal limit of the helical intertwining relationship was found at a mean distance of 20.0 ± 15.6 mm anterior and 53.7 ± 4.7 mm superior to the most anterosuperior point of the external auditory meatus. The cephalic limit of the helical intertwining relationship was found a mean distance of 24.7 ± 17.9 mm anterior and 62.7 ± 3.8 mm superior to the most anterosuperior point of the external auditory meatus. When present, the length of the helical intertwining relationship was 10.3 ± 0.4 mm.

The nerve was found to run superficial to the superficial temporal artery in three specimens (18.8 percent). These relationships were highly variable. A single cross type of relationship, with the nerve running over the artery, was seen (Fig. 4). Alternatively, a complex relationship with multiple branches of the auriculotemporal nerve running over the superficial temporal artery was also observed (Fig. 5).

In the hemifaces where no nerve/artery interaction was seen, it was observed that the nerve and

artery were either divergent or ran parallel to each other (Fig. 6). Results of measurements are summarized in Table 1.

DISCUSSION

Detailed anatomical studies of nerves implicated in peripheral trigger sites for migraine headaches are pivotal in advancing the field. Auricu-

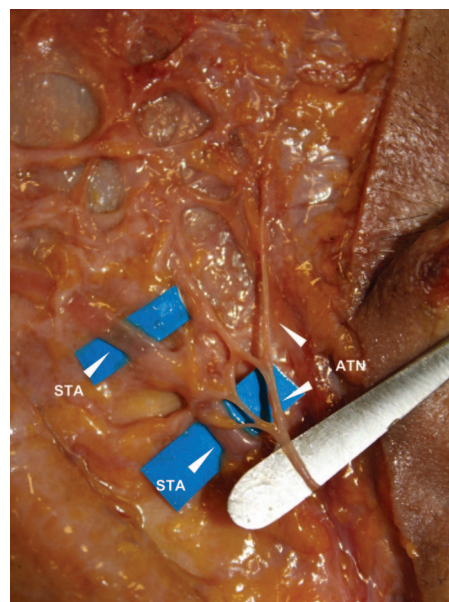


Fig. 5. Complex relationship of nerve and artery where branches of the auriculotemporal nerve (ATN) cross over the superficial temporal artery (STA) at multiple points.

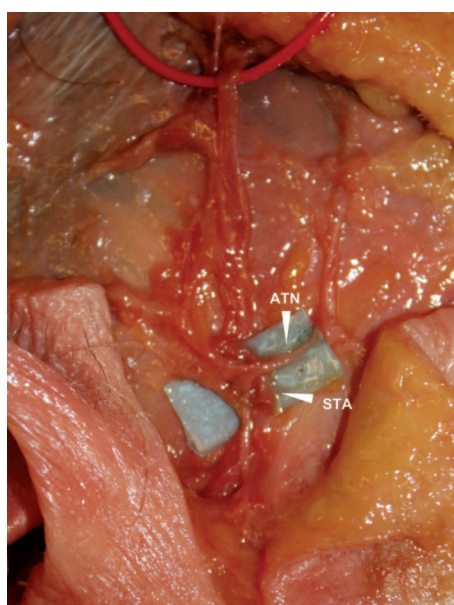


Fig. 4. Single cross relationship of the auriculotemporal nerve (ATN) superficial to the superficial temporal artery (STA).

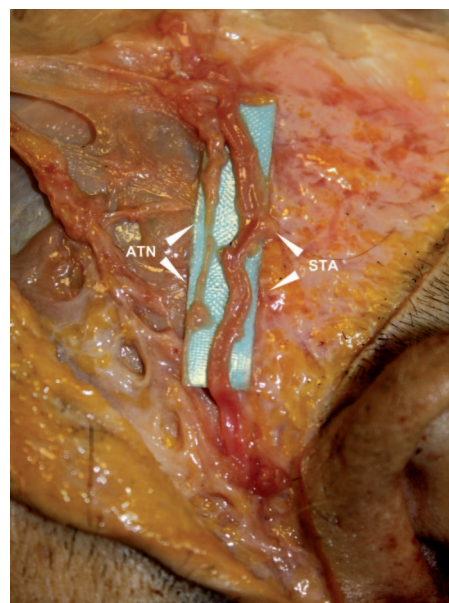


Fig. 6. The auriculotemporal nerve (ATN) runs parallel to the superficial temporal artery (STA), with no interaction of the two structures in this cadaver dissection.

Table 1. Compression Points around the Auriculotemporal Nerve*

| Distance from Anterosuperior EAM | Compression Points | | | | |
|----------------------------------|--------------------|--------|--------------|----------------|------------------|
| | 1 (mm) | 2 (mm) | Single Cross | 3 (mm) | |
| | | | | Helical-Caudal | Helical-Cephalic |
| Horizontal distance (anterior) | | | | | |
| Mean | 13.1 | 11.9 | 19.2 | 20.0 | 24.7 |
| SD | 5.9 | 6.0 | 10.0 | 15.6 | 17.9 |
| Vertical distance (superior) | | | | | |
| Mean | 5.0 | 17.2 | 39.5 | 53.7 | 62.7 |
| SD | 7.0 | 10.4 | 16.6 | 4.7 | 3.8 |

EAM, external auditory meatus.

*Hemifaces, $n = 20$.

lotemporal neuralgia has been described in the neurology literature as a syndrome “characterized by attacks of paroxysmal, moderate to severe pain on the preauricular area, often spreading to the ipsilateral temple.”¹⁰ The preauricular and temple compression points elucidated in this cadaver study correspond therefore with the previously loosely defined entity of auriculotemporal neuralgia. Auriculotemporal neuralgia has also been reported to cause toothache caused by referred pain from the external ear.¹¹ It is probable that the syndrome of “auriculotemporal neuralgia” may represent, in many cases, an undiagnosed compression of the auriculotemporal nerve leading to headaches. Surgical decompression would therefore be curative.

The findings in this study are similar to those presented in a recent anatomical study by Janis et al.⁸ We found a similar preponderance of the single cross type of artery/nerve interaction, with a rarer incidence of a helical intertwining relationship. However, we found a much higher incidence of an artery/nerve relationship in this study (80 percent in our study compared with 34 percent in the study by Janis et al.).⁸ The significant anatomical variation in the relationship between the auriculotemporal nerve and superficial temporal artery found in both studies likely explains this variance. Larger clinical or cadaver studies involving more hemifaces would be required to establish a true incidence of a significant artery/nerve interaction.

In clinical practice, the incidence of patients with migraine headaches localizing to the auriculotemporal nerve trigger point is extremely low compared with the incidence of an artery/nerve relationship found in this cadaver study. From these findings, it is logical to deduce that the genetic disposition to have migraine headaches is the most important factor in developing these symptoms from the scientific point of view. How-

ever, alteration of the anatomical setting can result in reduction or elimination of migraine headaches by deactivation of these trigger sites. The findings in this study suggest that in patients with preauricular pain, consideration should be given for exploration and decompression of the preauricular fascial bands (compression points 1 and 2).

CONCLUSIONS

Findings from this study provide support for the surgical decompression of the auriculotemporal nerve, implicated as a peripheral trigger point for migraine headaches. Potential compression points (compression points 1 and 2) in the preauricular course of the auriculotemporal nerve were found centered at 13.1 and 11.9 mm anterior and 5.0 and 17.2 mm superior to the most anterosuperior point of the external auditory meatus. A relationship was found between the auriculotemporal nerve and superficial temporal artery in the temple in 80 percent of hemifaces. These results have implications in surgical treatment of preauricular and supraauricular migraine headaches.

Bahman Guyuron, M.D.

Department of Plastic Surgery
Case Western Reserve University
University Hospitals of Cleveland, MS 5044
11100 Euclid Avenue
Cleveland, Ohio 44106
bahman.guyuron@gmail.com

REFERENCES

1. Guyuron B, Reed D, Kriegler JS, Davis J, Pashmini N, Amini S. A placebo-controlled surgical trial of the treatment of migraine headaches. *Plast Reconstr Surg*. 2009;124:461–468.

2. Calandre EP, Hidalgo J, Garcia-Leiva JM, Rico-Villademoros F. Trigger point evaluation in migraine patients: An indication of peripheral sensitization linked to migraine predisposition? *Eur J Neurol*. 2006;13:244–249.
3. Poggi JT, Grizzell BE, Helmer SD. Confirmation of surgical decompression to relieve migraine headaches. *Plast Reconstr Surg*. 2008;122:115–122; discussion 123–124.
4. Guyuron B, Kriegler JS, Davis J, Amini SB. Comprehensive surgical treatment of migraine headaches. *Plast Reconstr Surg*. 2005;115:1–9.
5. Janis JE, Dhanik A, Howard JH. Validation of the peripheral trigger point theory of migraine headaches: Single-surgeon experience using botulinum toxin and surgical decompression. *Plast Reconstr Surg*. 2011;128:123–131.
6. Guyuron B, Tucker T, Davis J. Surgical treatment of migraine headaches. *Plast Reconstr Surg*. 2002;109:2183–2189.
7. Dash KS, Janis JE, Guyuron B. The lesser and third occipital nerves and migraine headaches. *Plast Reconstr Surg*. 2005;115:1752–1758; discussion 1759–1760.
8. Janis JE, Hatef DA, Ducic I, et al. Anatomy of the auriculotemporal nerve: Variations in its relationship to the superficial temporal artery and implications for the treatment of migraine headaches. *Plast Reconstr Surg*. 2010;125:1422–1428.
9. Giamberardino MA, Tafuri E, Savini A, et al. Contribution of myofascial trigger points to migraine symptoms. *J Pain* 2007;8:869–878.
10. Speciali JG, Gonçalves DA. Auriculotemporal neuralgia. *Curr Pain Headache Rep*. 2005;9:277–280.
11. Murayama RA, Stuginski-Barbosa J, Moraes NP, Speciali JG. Toothache referred from auriculotemporal neuralgia: Case report. *Int Endod J*. 2009;42:845–851.

Plastic Surgery Level of Evidence Rating Scale—Diagnostic Studies



| Level of Evidence | Qualifying Studies |
|-------------------|---|
| I | Highest-quality, multicentered or single-centered, cohort study validating a diagnostic test (with “gold” standard as reference) in a series of consecutive patients; or a systematic review of these studies |
| II | Exploratory cohort study developing diagnostic criteria (with “gold” standard as reference) in a series of consecutive patient; or a systematic review of these studies |
| III | Diagnostic study in nonconsecutive patients (without consistently applied “gold” standard as reference); or a systematic review of these studies |
| IV | Case-control study; or any of the above diagnostic studies in the absence of a universally accepted “gold” standard |
| V | Expert opinion developed via consensus process; case report or clinical example; or evidence based on physiology, bench research, or “first principles” |

**Find out more from the “Evidence-Based Medicine: How-to Articles”
Collection at www.PRSJournal.com**