

# Anatomy of the Auriculotemporal Nerve: Variations in Its Relationship to the Superficial Temporal Artery and Implications for the Treatment of Migraine Headaches

Jeffrey E. Janis, M.D.

Daniel A. Hatef, M.D.

Ivica Ducic, M.D., Ph.D.

Jamil Ahmad, M.D.

Corinne Wong, M.R.C.S.

Ronald E. Hoxworth, M.D.

Timothy Osborn, D.D.S.

Dallas and Houston, Texas; Washington,  
D.C.; and Portland, Ore.

**Background:** Clinical experience with surgical decompression of specific peripheral nerves in the head and neck for the relief of migraine headache symptoms has proven to be effective in most patients. Some patients, however, continue to have residual symptoms after these procedures. In an effort to better understand potential etiologies for failure of treatment, an investigation was performed to determine whether or not vascular-mediated peripheral trigger points exist that have heretofore been undescribed that may be contributing to persistent symptomatology. One such potential trigger point is the superficial temporal artery's interaction with the auriculotemporal nerve. A cadaveric investigation was performed to advance this anatomical understanding of this relationship.

**Methods:** Both sides of 25 fresh cadaveric heads were dissected in the preauricular and temporal regions. The superficial temporal artery and auriculotemporal nerve were identified and dissected both proximally and distally. Their relationship was examined, and a topographical map of their intersections was generated.

**Results:** The auriculotemporal nerve and superficial temporal artery run together in the superficial soft tissue in the preauricular and temple regions. A contiguous relationship between the two was found in 17 hemiheads (34.0 percent).

**Conclusions:** There are variations in the relationship between the auriculotemporal nerve and the superficial temporal artery. These variations may serve as an anatomical explanation for this point as a source of migraine headaches in some patients. A topographical map of the relationship between these two structures may serve as a guide for surgeons interested in decompressing the nerve from the artery when indicated. (*Plast. Reconstr. Surg.* 125: 1422, 2010.)

**T**raditional teaching regarding the etiology of migraine headaches has instructed that there exists a centrally based trigger within the brain.<sup>1</sup> Neurologists have recently begun to focus on pathways between the central nervous system and peripheral nerves in the head and neck, specifically the trigeminal and greater occipital nerves.<sup>2</sup> In addition, plastic surgeons have

demonstrated that many patients achieve migraine relief with corrugator resection.<sup>3,4</sup> These findings may require reexamination of the classic understanding of migraines, as these results suggest that there may be a peripherally mediated cause of migraine headaches<sup>5</sup>; this is not unlike upper extremity compression syndromes, where irritation, compression, or entrapment of peripheral nerves at one or several points along its course results in significant symptomatology.<sup>6</sup>

This novel concept of peripheral "trigger points" has led to a number of different clinical

*From the Departments of Plastic Surgery of University of Texas Southwestern Medical Center, Baylor College of Medicine, and Georgetown University Medical Center, and the Division of Oral and Maxillofacial Surgery, Oregon State University Health Sciences Center.*

*Received for publication January 7, 2009; accepted November 23, 2009.*

*Copyright ©2010 by the American Society of Plastic Surgeons*

DOI: 10.1097/PRS.0b013e3181d4fb05

**Disclosure:** *The authors have no financial interest to declare in relation to the content of this article.*

interventions. Injection of botulinum toxin has been shown to be clinically effective,<sup>6–9</sup> albeit only for the duration of its chemodenervation. It has also been used as a diagnostic tool to predict surgical success.<sup>5,10</sup> Surgical decompression has led to significant migraine relief in a majority of patients, specifically release of the supraorbital, supratrochlear, zygomaticotemporal, and greater occipital nerves.<sup>11,12</sup>

Despite these early successes, however, there remain some patients who do not respond—symptomatic improvement is seen in some while others get no durable relief. Guyuron et al. have reported that corrugator resection leads to improvement in symptoms in over 80 percent of patients, with complete resolution in 55 percent.<sup>3</sup> The occipital region was found as another trigger point region, and decompression of the greater occipital nerve has been shown to cure 62 percent of migraine patients.<sup>13</sup> Although these results are very good, with long-term relief brought to many patients, there are still patients who do not benefit from this intervention. This begs the question as to whether these patients' migraine are (1) of a central genesis, (2) another headache type misdiagnosed as migraine, (3) from a trigger point that has undergone incomplete surgical decompression, or (4) from a trigger point that has not been addressed at all. The third and fourth third possibilities have led to further anatomical investigations for other potential peripheral trigger points, as well as investigation into whether previously described trigger points have more than one area of compression along their course.<sup>13–16</sup> Specific attention has also been paid to the relationship between these peripheral nerve and adjacent arteries that may intersect or intertwine with these nerves in such a way as to cause irritation and therefore trigger a migraine headache.

The senior authors on this article (J.E.J. and I.D.) have seen patients in whom the main complaint in terms of pain appears to be the high temple region. Release of the zygomaticotemporal and supraorbital nerves has led to symptomatic relief in many of these patients, but a minority of patients have not seen the benefit of this procedure. It was postulated that the auriculotemporal nerve, which is a branch of the trigeminal nerve and located specifically in this region, could be a source of migraine pain. It is further surmised that in these patients there may be an intersection of the superficial temporal artery and auriculotemporal nerve caus-

ing irritation. To more fully elucidate the relationship between these two structures, an anatomical study was designed and executed.

### RELEVANT ANATOMY

Although the anatomy of the auriculotemporal nerve has not been widely discussed, the general course of the nerve is well understood. It is a branch of the third division of the trigeminal nerve, which enters the facial soft tissue within the superficial substance of the parotid gland posterior to the region overlying the temporomandibular joint. It can often divide into more than one branch as it moves over the posterior portion of the zygomatic arch and travels cranially within the layers of temporoparietal fascia. The auriculotemporal nerve provides cutaneous sensation to the tragus and anterior portion of the ear, along with the posterior portion of the temple. In addition, it provides sympathetic innervation to the scalp and parasympathetic innervation to the parotid gland.

Surgeons and anatomists have dissected this nerve in some detail in the regions of the infratemporal fossa and the temporomandibular joint. It has been demonstrated that the nerve has one branch in 50 percent of specimens, while multiple branches (up to four) can be present in the other 50 percent of specimens.<sup>17</sup> Occasionally, connecting branches may be seen between the nerve and both the inferior alveolar nerve and facial nerve branches in this region. In the region of the temporomandibular joint, the nerve passes medially to this structure. It has been shown to be closely related to the upper portion of medial side of the mandibular condyle and the capsule of the joint.<sup>18</sup> Although the anatomy of this nerve in its more proximal regions has been previously explored, its course within the soft tissues of the temple and its relationship with the superficial temporal artery have not been elucidated.

The intimate relationship between the auriculotemporal nerve and the superficial temporal artery is not a new concept. In *Gray's Anatomy*, the nerve is described as having connections with the facial nerve, which may loop around the transverse facial and superficial temporal vessels.<sup>19</sup> It was recently demonstrated that the auriculotemporal nerve occasionally has two branches that surround the middle meningeal artery when they exist in this pair.<sup>18</sup> The anatomical location, extent, and the different phenotypic arrangements of these relationships, however, have not been meted out. The close anatomical relationship between the auriculotemporal nerve and the superficial tem-

poral artery has not been examined in depth; that relationship is the focus of the project disclosed in this article.

## METHODS AND MATERIALS

Twenty-five fresh cadaver heads were obtained from the Willd Body Program at the University of Texas Southwestern Medical Center, in Dallas, Texas. All donors were between the ages of 42 and 86 years and were tested for human immunodeficiency virus and other communicable diseases.

The heads were shaved and stabilized in a Mayfield neurosurgical headrest in the supine position. A horizontal line from the nasion through the lateral orbital rim was drawn with a surgical marker; a ruler was used to extend this line through the inferior temple. A methylene blue-tipped 16-gauge needle was passed through the skin to mark the subcutaneous tissue along this line for accurate measurements during dissection. A surgical marker was then used to mark a line vertically through the facial midline from the nasion through the menton.

A no. 15 blade was used to make an incision through a standard preauricular face lift incision, and the superficial musculoaponeurotic system was identified and dissected over the zygomatic arch. The superficial temporal artery and the auriculotemporal nerve were identified at this level and dissected cranially. The structures were widely exposed and their relationship was examined. Their intimate relationship was measured in length, measured from the previously noted anatomical landmarks, and photographed.

For better visualization, the superficial temporal artery was dissected proximally, ligated, and cannulated with a 24-gauge butterfly catheter (0.7-mm diameter; BD Insyte; Becton Dickinson S.A., Madrid, Spain). Lead oxide stained with red dye was heated and injected into the arteries. This was allowed to set, and photographs were taken.

All data were put into a Microsoft Excel database (Microsoft, Inc., Redmond, Wash.). Means and standard deviations were calculated for the distances from the horizontal line through the nasion-lateral orbital rim and from the midline, as well as for the length of the relationships between the artery and nerve.

## RESULTS

The preauricular and temple regions of both sides of 25 fresh tissue cadaveric heads were dissected. Seventeen of these heads were from male

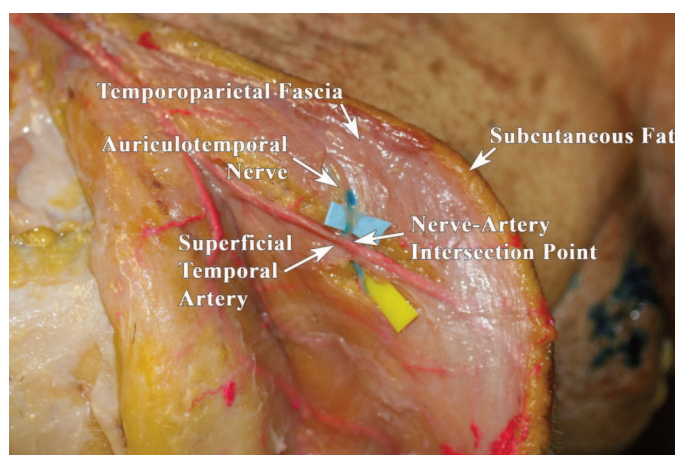
cadaveric donors, and eight were from female donors, with an overall mean age of 61 years (range, 50 to 81 years). The auriculotemporal nerve and superficial temporal artery were found in all 50 hemiheads.

The superficial temporal artery was always located first, running within the substance of the superficial temporal fascia. The auriculotemporal nerve was found in the upper preauricular area after its travel posterior to the area overlying the temporomandibular joint and over the posterior portion of the zygomatic arch. Sometimes more than one branch of the nerve existed. The nerve was always found to be lateral to the artery in the upper preauricular region of the temple. As the artery and nerve coursed more cranially, they became slightly more superficial, lying on top of the superficial temporal fascia, with the nerve often arborizing into two branches (Fig. 1). A direct relationship was found between the two structures in 17 specimens (34.0 percent). When present, this intersection was found at a distance of 107.88 mm lateral to the midline (SD, 17.73 mm) and 37.53 mm cranial to the continuation of the horizontal line from the nasion through the lateral orbital rim (SD, 15.29 mm) (Fig. 2). This relationship was nearly always a short, discrete intersection ( $n = 15$ ; 88.2 percent) (Fig. 3); however, in two cases there was a helical intertwining of the two structures (11.8 percent) (Fig. 4). These relationships had a mean length of 21 mm, with a mean beginning at 123 mm lateral to the midline and 25 mm cranial to the nasion-lateral orbit line and a mean ending at 117 mm lateral to the midline and 38 mm cranial to the nasion-lateral orbit line (Table 1).

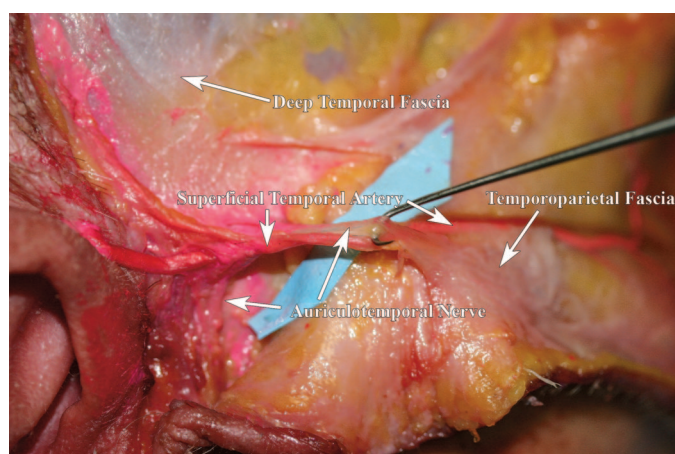
## DISCUSSION

The auriculotemporal nerve–superficial temporal artery relationship has been implicated as a trigger point for migraine headaches. In 34.0 percent of the cranial halves investigated in this study, there was found to be a direct relationship between this artery and nerve. Because of the anatomical location of this relationship, which was always found to be in the soft tissues in the temple region, it would be readily amenable to surgical treatment through ligation of the artery (proximal and distal) through a small incision within the temporal hairline. This is suggested as a possible new procedure to induce migraine cure in patients with refractory migraines in whom the high temple region is felt to be a trigger point.





**Fig. 1.** Dissection in the left temple region. The flap has been dissected deep to the temporalparietal fascia. The superficial temporal fat pad lies down. The auriculotemporal nerve can be seen crossing on top of the superficial temporal artery. This illustrates a “single cross” type of nerve-artery relationship.

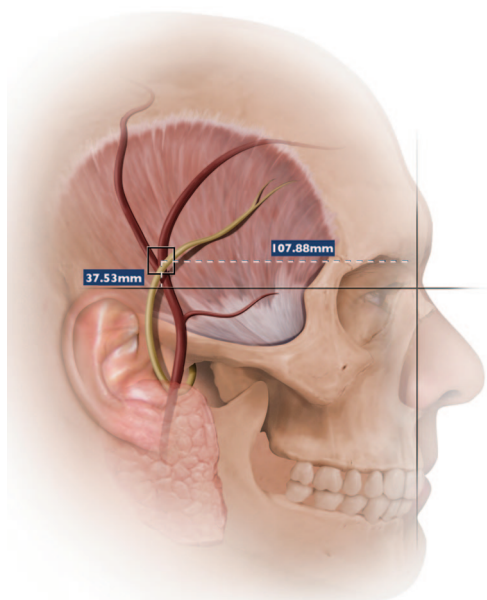


**Fig. 2.** Dissection in the right temple. The superficial temporal artery and auriculotemporal nerve are wrapping around each other. This illustrates an “intertwining” type of nerve-artery relationship.

The anatomical details revealed in this investigation demonstrate that the auriculotemporal nerve has a potential compression site when it has a relationship with the superficial temporal artery. This relationship is demonstrated to be very intimate when present; at some sites, there is a helical intertwining of the nerve around the artery. With some patients complaining of symptoms generating from this region, it stands to reason that this may represent a peripheral trigger point that has gone undescribed. This may also represent a reason for failure of prior treatment in some patients.

The anatomical relationships between this nerve and surrounding arteries are clearly of in-

terest. Many migraine headaches are described as being “pulsatile” in nature. Perhaps that could be caused by pulsatile irritation of these nerves by intimately adjacent arteries, such as that described here, and the greater occipital nerve–occipital artery interaction.<sup>16</sup> The fact that the nerve-artery relationship does not exist in all individuals, and that when it does, it has a variable relationship, may explain why some people have migraine headaches seemingly originating from this region whereas others do not. This is not the only anatomical site where there is variability in a nerve-artery relationship. Other recent anatomical studies from this group implicate the occipital artery as being a potential site of entrapment and irri-



**Fig. 3.** Illustration depicting the mean location for the intersection of the auriculotemporal nerve and superficial temporal artery. This roughly corresponds with the locus of migraine genesis that many patients with a temple region trigger point have.

tation for the greater occipital nerve.<sup>16</sup> In 54.0 percent of specimens, it was found that there is a relationship between these structures. About 70 percent of these intimate anatomical relationships were of the helical type, whereas approximately 30 percent were a single cross.

This is not the first article in which the data described may indicate that there could be an arterial genesis of neurological pain symptoms. Oral and maxillofacial surgeons are experienced in the realm of the management of facial pain syndromes, and some authors in this body of literature have suggested that some orofacial pain may have its mechanism in the neurovascular entrapment of the maxillary artery and inferior alveolar nerve.<sup>20</sup> Specifically, some authors have suggested that when standard techniques for the relief of trigeminal neuralgia are ineffective, the intimate relationship between these two structures may be at fault.<sup>21,22</sup>

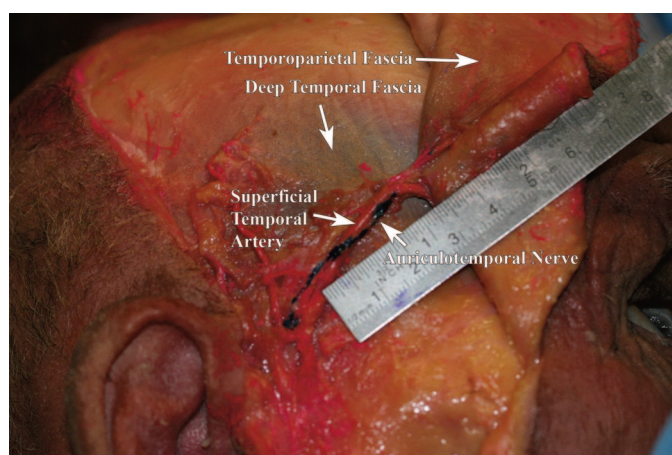
The auriculotemporal nerve has been implicated in other pain and neurological syndromes as well. Auriculotemporal neuralgia is a well-recognized headache disorder characterized by paroxysmal attacks of pain in the preauricular area, sometimes spreading over the temple region.<sup>23</sup> Frey's syndrome is gustatory sweating, which is an occasional complication of parotid surgery. This is caused by aberrant regeneration of innervation; after surgical division, the sympathetic fibers to

the scalp grow to innervate the parotid gland and the parasympathetic fibers innervate the scalp. This aberrancy leads to "gustatory sweating," in which instead of producing saliva, the patient sweats while eating.

Other branches of the trigeminal nerve have been shown to be involved with tic douloureux, which is a painful neuralgia in a region of the face that receives its sensory innervation from the trigeminal nerve. Patients with Frey's syndrome have sometimes also had a concomitant onset of tic douloureux, demonstrating the possibility that injury to the auriculotemporal nerve can cause pain symptoms in regions innervated by more proximal portions of the trigeminal nerve system.<sup>24</sup>

The potential weakness in this study is that it was carried out in fresh tissue cadavers from patients who had died in old age. Clearly structural anatomical data are clinically translatable; however, it must be noted. Perhaps in vivo anatomical study would augment these findings. Duplex ultrasound or high-resolution magnetic resonance imaging might allow us to ascertain these relationships in vivo and also allow for dynamic study of their interaction during facial animation. As well, we did not specifically investigate whether or not there was any difference in female versus male specimens. This may be an important point, as female patients are much more likely than males to suffer from migraine headaches. It is felt, however, that this incidence is likely related to hormonal, rather than structural, differences between the sexes.

Continued investigation into the detailed anatomy of the peripheral branches of the trigeminal nerve is warranted, as this will yield more information concerning potential compression points and sites where nerve irritation may occur. The existence of multiple sites of compression along the path of peripheral nerves in the head and neck is anatomically consistent, with experience in peripheral nerve decompression elsewhere in the body (for example, upper extremity compression syndromes).<sup>25</sup> It is probable that surgical decompression of multiple sites will be necessary for clinical relief of migraines in some patients, just as it is frequently needed for patients with upper extremity compression syndromes.<sup>26,27</sup> Whether these compression points are intersections with contractile muscle, tight fascial bands, or intersections with adjacent structures, such as arteries, is largely irrelevant in the strictest terms, as they merely represent different "flavors" of compression, irritation, or entrapment. What makes identification of these points of potential com-



**Fig. 4.** Dissection in the right temple. Again, the superficial temporal artery and auriculotemporal nerve are seen in the “intertwining” type of nerve-artery relationship.

**Table 1. Results of Dissection**

Facial Halves	<i>n</i> = 50
Nerve-artery relationship found	17/50 (34%)
Mean intersection distance lateral to midline	107.88 mm
Mean intersection cranial to horizontal line from nasion through orbital rim	37.53 mm

pression relevant is how they are addressed. If muscle, it can be chemodenervated as a test, and then subsequently surgically decompressed. If fascia, it can be surgically released. If arterial, it can be ligated or embolized to remove its effect on the adjacent peripheral nerve.

## CONCLUSIONS

Due to the clinical failure of surgical decompression of the supraorbital, supratrochlear, and zygomaticotemporal nerves in some patients with frontal and/or temporal trigger point migraines, and due to persistent clinical symptoms of pain in the temple and scalp region, an anatomic investigation into the relationship between the auriculotemporal nerve and superficial temporal artery was performed. In 25 fresh cadaveric heads, it was found that there is an intimate relationship between the nerve and artery in 34 percent of all facial halves. In some cases, this was a brief intersection, whereas in others, the relationship was a series of intertwining loops around each other. It is proposed that this nerve may serve as a trigger point for migraine headaches in some patients and that ligation of the superficial temporal artery proximal and distal to this intersecting region may give full decompression in these patients. Further

clinical work is needed to assess whether this will yield more success; future studies will be directed toward examining this region for other potential sites of compression.

**Jeffrey E. Janis, M.D.**

Department of Plastic Surgery  
University of Texas Southwestern Medical Center  
1801 Inwood Road  
Dallas, Texas 75390-9132  
jeffrey.janis@utsouthwestern.edu

## REFERENCES

1. Sanchez del Rio M, Reuter U. Pathophysiology of headache. *Curr Neurol Neurosci Rep.* 2003;3:109.
2. Dalkara T, Zervas NT, Moskowitz MA. From spreading depression to the trigeminovascular system. *Neurol Sci.* 2006; 27:86.
3. Guyuron B, Varghai A, Michelow BJ, Thomas T, Davis J. Corrugator supercilii muscle resection and migraine headaches. *Plast Reconstr Surg.* 2000;106:429.
4. Guyuron B, Tucker T, Davis J. Surgical treatment of migraine headaches. *Plast Reconstr Surg.* 2002;109:2183.
5. Guyuron B, Kriegler JS, Davis J, Amini SB. Comprehensive surgical treatment of surgical migraines. *Plast Reconstr Surg.* 2005;115:1.
6. Janis JE, Hatef DA, Reece EM, Hamawy AH, Becker S, Guyuron B. The anatomy of the greater occipital nerve: Part II. Compression point topography. *Plast Reconstr Surg.* (in press).
7. Gobel H, Heinze A, Heinze-Kuhn K, Jost WH. Evidence-based medicine: Botulinum toxin A in migraine and tension-type headache. *J Neurol.* 2001;248(Suppl. 1):34.
8. Wheeler AH. Botulinum toxin A, adjunctive therapy for refractory headaches associated with pericranial muscle tension. *Headache* 1998;38:468.
9. Silberstein S, Mathew N, Saper J, Jenkins S. Botulinum toxin type A as a migraine preventive treatment. *Headache* 2000; 40:445.
10. Behmand RA, Tucker T, Guyuron B. Single-site botulinum toxin type A injection for elimination of migraine trigger points. *Headache* 2003;43:1085.



11. Guyuron B, Reed D, Kriegler JS, Davis J, Pashmini N, Amini S. A placebo-controlled surgical trial of the treatment of migraine headaches. *Plast Reconstr Surg*. 2009;124:461.
12. Janis JE. A placebo-controlled surgical trial of the treatment of migraine headaches (Discussion). *Plast Reconstr Surg*. 2009;124:469.
13. Totonchi A, Pashmini N, Guyuron B. The zygomaticotemporal branch of the trigeminal nerve: An anatomical study. *Plast Reconstr Surg*. 2005;115:273.
14. Mosser SW, Guyuron B, Janis JE, Rohrich RJ. The anatomy of the greater occipital nerve: Implications for the etiology of migraine headaches. *Plast Reconstr Surg*. 2004;113:693.
15. Dash KS, Janis JE, Guyuron B. The lesser and third occipital nerves and migraine headaches. *Plast Reconstr Surg*. 2005;115:1752.
16. Janis JE, Hatef DA, Reece EM, McCluskey P, Schaub TA, Guyuron B. The anatomy of the greater occipital nerve: Part III. Relationship with the occipital artery. *Plast Reconstr Surg*. (in press).
17. Gulekon N, Anil A, Poyraz A, Peker T, Turgut HB, Karakose M. Variations in the anatomy of the auriculotemporal nerve. *Clin Anat*. 2005;18:15.
18. Schmidt BL, Pogrel MA, Necoechea M, Kearns G. The distribution of the auriculotemporal nerve around the temporomandibular joint. *Oral Surg Oral Med Oral Pathol Oral Radiol Endod*. 1998;86:165.
19. Standring S, ed. *Gray's Anatomy*. 39th ed. London: Elsevier; 2005:513.
20. Yoshino N, Akimoto H, Yamada I, et al. Trigeminal neuralgia: Evaluation of neuralgic manifestation and site of neurovascular compression with 3D CISS MR imaging and MR angiography. *Radiology*. 2003;228:539.
21. Decuadro-Saenz G, Castro G, Sorrenti N, et al. Auriculotemporal nerve: Neuroanatomic bases of the Frey's syndrome. *Neurocirugia (Astur)*. 2008;19:218.
22. Anil A, Peker T, Turgut HB, Gulekon IN, Liman F. Variations in the anatomy of the inferior alveolar nerve. *Br J Oral Maxillofac Surg*. 2003;41:236.
23. Speciali JG, Goncalves DA. Auriculotemporal neuralgia. *Curr Pain Headache Rep*. 2005;9:277.
24. De Benedittis G. Auriculotemporal syndrome (Frey's syndrome) presenting as tic douloureux: Report of two cases. *J Neurosurg*. 1990;72:955.
25. Hayes CW. Compression neuropathies in the upper limb. In Aston SJ, Beasley R, Thorne CHM, eds. *Grabb and Smith's Plastic Surgery*. 5th ed. Philadelphia: Lippincott-Raven; 1997:917.
26. Lundborg G, Dahlin LB. The pathophysiology of nerve compression. *Hand Clin*. 1992;8:215.
27. Ruchelsman DE, Lee SK, Posner MA. Failed surgery for ulnar nerve compression at the elbow. *Hand Clin*. 2007;23:359.

## PRS Online

Gain access to the full spectrum of plastic and reconstructive surgery. Visit *Plastic and Reconstructive Surgery's* Web site, [www.PRSJournal.com](http://www.PRSJournal.com) today!

Every subscription to the print edition of *PRS* includes full access to the online *Journal*. PRS-Online contains the complete text and figure content of the print *Journal*, and has these additional features:

- Article+ items (short-duration videos and animations)
- Video+ videos (high-resolution streaming videos of operative procedures)
- Podcasts of selected article abstracts—download PRS abstracts and listen on the go
- CME articles and tests—earn up to 14 Category 1 CME credits/year
- CME Contemporary Collections (CME articles grouped by section)
- Advance Online articles (preprint publication of selected clinical and experimental articles)
- Key images from each section, including Image of the Month
- Calendar of future meetings and events
- Links to the ASPS homepage and other sister society links

In order to activate the full content of PRS-Online, you must register. Registration is a quick, one-time process.

To register:

- Go to [www.PRSJournal.com](http://www.PRSJournal.com).
- Click "Register" on the top menu bar.
- Follow the activation instructions that appear on the screen.
- ASPS members, please have your ASPS member number ready.